CALYX™

/

CASE STUDY

Medical Imaging in Rare Disease Trials

Hypertrophic Obstructive Cardiomyopathy (HOCM)

OVERVIEW

Clinical trial sponsors face many challenges when medical imaging is used to evaluate the safety and efficacy of new medical treatments. These challenges are even more significant when the treatment is being developed for rare diseases. Medical imaging plays an important role in these trials as it provides a non-invasive way to assess treatment response.

As a requirement, most rare disease clinical trials are multicentre, and often multinational for sufficient patient recruitment, even in phase I and II trials. This can challenge clinical study protocol harmonization, the selection of appropriate biomarkers, ethical review, site IRB approval, indemnity, organization of clinical services, standards of care, and cultural diversity.

And, most diagnoses classified as rare diseases affect numerous body systems. It's not unusual for a patient with a rare disorder to have symptoms and/or underlying disease that affects their cardiovascular, neurological, and respiratory systems, among others. As a result, the sponsor's selected imaging partner should possess broad expertise across all therapeutic areas and a thorough understanding of the imaging modalities typically used across each rare disease and body system.

Additionally, as there are not many people living with the diagnosis, finding patients and keeping them engaged in clinical trials is critical. Trial sponsors can't risk a patient dropping out of a study because imaging processes were not performed correctly (i.e, requiring the patient to repeat scans, etc.) or the imaging analysis is unreliable.

Significant progress has been made in our understanding of the biological basis of disease mechanism for rare diseases. This has been possible with the use of novel laboratory, analytical, and imaging techniques combined with the expertise and hard work of scientists and physicians taking care of these patients. Leveraging the expertise of these scientists and physicians is important while designing and executing rare disease clinical trials.

For these and many other reasons, trial sponsors need an imaging provider with a combination of robust, proven processes, extensive experience, and far-reaching scientific expertise for medical imaging to be used effectively and reliably during the clinical development of rare disease treatments.

CASE STUDY - HOCM

BACKGROUND:

Hypertrophic cardiomyopathy (HCM) is the most common genetic heart disease in the US, with an estimated prevalence of 1 in 500. HCM is a chronic, progressive disease which over time results in tissue remodeling characterized histologically by myocyte hypertrophy and disarray, microvascular remodeling, and fibrosis. Two HCM types are obstructive HCM (oHCM or HOCM) and non-obstructive HCM that are recognized based on the presence or absence of obstruction of the left ventricular outflow tract (LVOT).

IMAGING IN HOCM

Various imaging modalities can be used to assess cardiac structure and function, the presence and severity of LVOT obstruction and tissue characteristics. Transthoracic echocardiography and cardiac MRI (CMR) remain the imaging modalities of choice in the diagnosis and clinical management of HOCM. In clinical trials, echocardiography and CMR can support eligibility criteria and efficacy endpoints.

Echocardiography

Echocardiography is a non-invasive imaging modality that has high diagnostic accuracy and is considered one of the most commonly performed imaging tests to provide valuable information on the key features of HOCM. Echo is widely available and relatively inexpensive, making it attractive for collection of imaging data across multiple investigator sites participating in clinical trials. It can provide great insight on cardiac structure and function in patients with HOCM such as Left Ventricular (LV) myocardial thickness, changes in LV ejection fraction (LVEF), and LVOT peak pressure gradients.

Cardiac MRI

CMR is valuable in evaluating the disease severity and characterizing the morphological and functional pathology of HOCM.

Standard CMR images in cine mode can reliably assess cardiac structure and function, e.g., LV or left atrial (LA) volumes, LV wall thickness. Advanced CMR techniques can provide quantitative assessment in pathological changes due to HOCM at a cellular level. Late gadolinium (Gd) enhancement (LGE) imaging is used to quantify myocardial fibrosis mass. CMR methods such as T1 and T2 mapping can show myocardial injuries related to HOCM without using a contrast agent. T1 mapping with Gd-based contrast is utilized to measure the extracellular volume fraction which is elevated due to cellular hypertrophy.

STUDY IMPLEMENTATION

Calyx Medical Imaging supported a Phase III clinical trial in which the sponsor was evaluating a new treatment for symptomatic HOCM. The clinical trial included 15 sites with over 130 screened and 81 enrolled subjects. Both echocardiography and CMR were included to support eligibility and efficacy assessments in the HOCM clinical trials.

Echocardiography was the modality of choice to screen patients, meet study primary and secondary endpoints, and support dose titration. The imaging protocol consisted of echo images obtained at rest and with Valsalva maneuvers which made the image acquisition complex. To ensure harmonization of all incoming imaging data, the Calyx Medical Imaging team worked with sites to train the sonographers on all aspects of image acquisition and patient preparation.

All echo images were analyzed by independent reviewers (cardiologists) who were trained on the study-specific image analysis protocol. To maintain independent reads in a standardized manner, the Calyx study team monitored reviewer performance throughout the study, making sure that all readers adhered to the review assessment criteria and maintained reader-to-reader variability at an acceptable level. All resulting data was checked by the Calyx team for accuracy and completeness prior to reporting.

CMR supported the trial's secondary and exploratory endpoints, having been used to assess cardiac structure and function, myocardial fibrosis, and extracellular volume fraction. These CMR assessments required a complex CMR acquisition protocol with both standardized and novel CMR imaging sequences. Calyx developed a customized image acquisition protocol for this study. Because of the highly complex nature of the acquisition protocol and to maximize the consistency and quality of CMR images across all participating sites, Calyx's Scientific and Medical team worked closely with each site to optimize the CMR protocol specific to the site's scanner and reviewed the quality of each CMR sequence in detail.

As the clinical trial included different types of CMR assessments and all assessments required contour placement, we streamlined a workflow to optimize the usage of the reviewers' time and minimize reader variability. To ensure the accuracy of CMR data review, Calyx identified and recruited reviewers/cardiologists who are experts in the field, conducted thorough reviewer training on the assessment criteria, and continued monitoring reviewer performance.

RESULTS

Site qualification and all baseline imaging were successfully completed for echocardiography and CMR. The success of the site initiation/qualification process resulted from rigorous image quality checks of test transfer from participating investigator sites, site communication, and query management.

Calyx Medical Imaging successfully supported all subject enrollments, providing independent verification of specific imaging-based inclusion/exclusion criteria using echocardiography with a short turn-around-time. At the time of this writing, the sponsor had concluded patient enrollment and recognized Calyx's expertise and diligence in delivering timely independent analysis results. The sponsor continues to rely on Calyx Medical Imaging for the image acquisition and review that will support the study's primary efficacy endpoint.

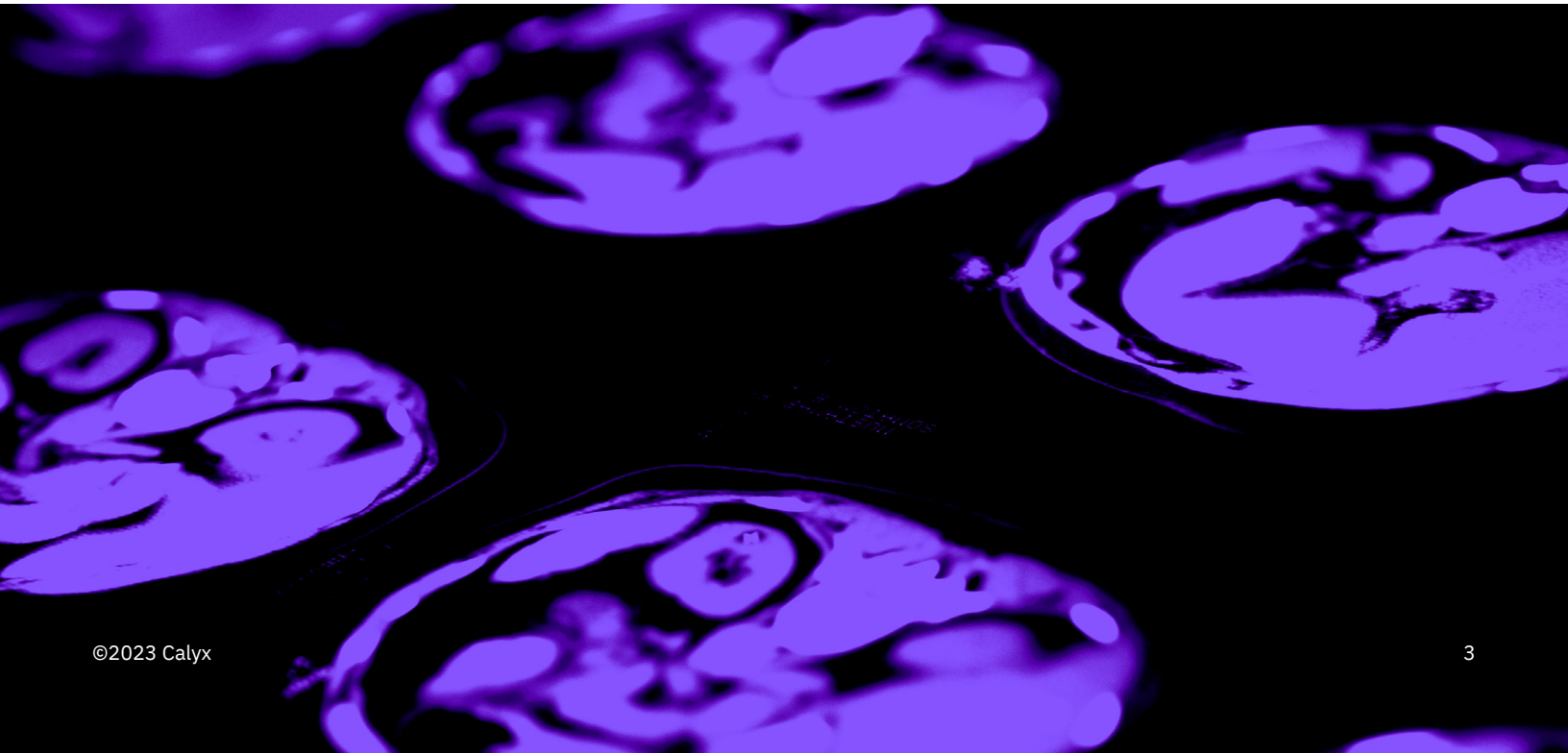

CALYX EXPERIENCE IN RARE DISEASE STUDIES

Calyx Medical Imaging's experience is drawn from managing over 2,600 trials to date which include more than 4.4 million images from roughly 155,000 sites globally. Within this experience is our management of over 170 rare disease trials, which have led to the approval of over 20 indications classified as rare diseases.

INDICATION	# OF TRIALS	# OF SUPPORTED APPROVALS	MODALITIES
Amyloidosis	2		Nuclear medicine, echocardiography
Autosomal Dominant Polycystic Kidney Disease (ADPKD)	14	3	MRI
Cystic Fibrosis	1		HRCT
Esophagitis	6	1	Endoscopy and Photography
Fabry Disease	3		ECHO, CT, MRI
Fibrodysplasia Ossificans Progressive (FOP)	7	1	DXA, X-ray, MRI, Ultrasound, WB-CT
Gaucher's Disease (Endocrine)	3		DXA, X-ray, MRI, CT
Hereditary Hemochromatosis (HH)	1		CFP
Hypertrophic Obstructive Cardiomyopathy (HOCM)	2		Echo, cardiac MRI
Idiopathic Pulmonary Fibrosis (IPF)	29	4	HRCT, MDCT, Surgical Lung Biopsy/Pathology (SLB)
Mantle Cell Lymphoma	19	4	CT, MRI, PET, Bone Scan, Skin Lesions
Merkel Cell Carcinoma (MCC)	2		CT, MRI, Brain Scan, Photography, FDG-PET
Muscular dystrophy	6		DXA, MRI
Mutated Rare Cancers	1		CT, MRI, Brain
Neuroendocrine Tumors	5		CT, MRI, Bone scan
Neurofibromatosis, NF1 or NF2	10	1	MRI, Photography
Osteogenesis Imperfecta	1		X-ray, DXA
Pancreatic Ductal Adenocarcinoma	35		CT, MRI, Brain Scan, X-ray, Bone Scan
Pediatric B-Cell Lymphoma (NHL)	1		CT, MRI, PET-CT
Pulmonary Hypertension (Pulmonary Disorder) (Pediatric)	4		Cardiac MRI, ECHO, HRCT
Pulmonary Sarcoidosis (Respiratory)	7		HRCT, PET-CT, X-ray, cMRI (cardiac MRI)
Scleroderma Lung	1		HRCT, CT
Sickle Cell	4		MRI, MRI CNS, DXA, MUGA
Systemic Sclerosis Interstitial Lung Disease (SSc-ILD)	2		HRCT
T-Cell Lymphoma	14		CT, MRI, FDG-PET, Photograph

Thalassemia (Hematology)	4		CT, MRI, DXA, MUGA
Transfusional Hemosid-erosis	1		ECHO
Adrenoleukodystrophy (ALD)	1		Brain MRI
Waldenstrom's	7	5	CT, MRI, FDG-PET
Smoldering Myeloma	2		MRI, FDG-PET, CT
CNS Lymphoma	39		CT, Brain MRI, DWI/PWI, X-ray, Bone Scan, PET, SPECT, ECHO
Adult-onset leukoen-cephalopathy with axonal spheroids and pigmented glia (ALSP)	2		Brain MRI
Multiple system atrophy (MSA)	1		PET/CT
Encephalitis	2		MRI

Contact hello@calyx.ai to learn how Calyx Medical Imaging and our dedicated experts can design and deliver high quality Medical Imaging to drive your trial's success.

CALYX™

Reliably solving the complex.

calyx.ai
contact us at: hello@calyx.ai